Ph I/II Study of Oral Selective AXL Inhibitor Bemcentinib (BGB324) in Combination with Erlotinib in Patients with EGFRm NSCLC

L. Byers[1], K. Gold[2], J. Peguero[3], M.L. Johnson[4], J. Nieva[5], W.A. Harb[6], I. Rybkin[7], A. Chiappori[8], J. Strauss[9], David.E. Gerber[10]

(1) MD Anderson Cancer Center, Houston, TX (2) Moores UC San Diego Cancer Center, San Diego, CA (3) Oncology Consultants, Houston, TX (4) Tennessee Oncology, Nashville, TN (5) Norris Comprehensive Cancer Center, Los Angeles, CA (6) Horizon Oncology, Lafayette IN (7) Henry Ford Hospital, Detroit MI (8) Moffitt Cancer Center, Tampa, FL (9) Mary Crowley, Dallas TX (10) Harold C. Simmons Comprehensive Cancer Center, University of Texas Southwestern Medical Center

Background & objective

Bemcentinib (BGB324): selective, oral small molecule inhibtor of AXL in phase II clinical testing

Bemcentinib is developed in combination with immune-, targeted and chemotherapy

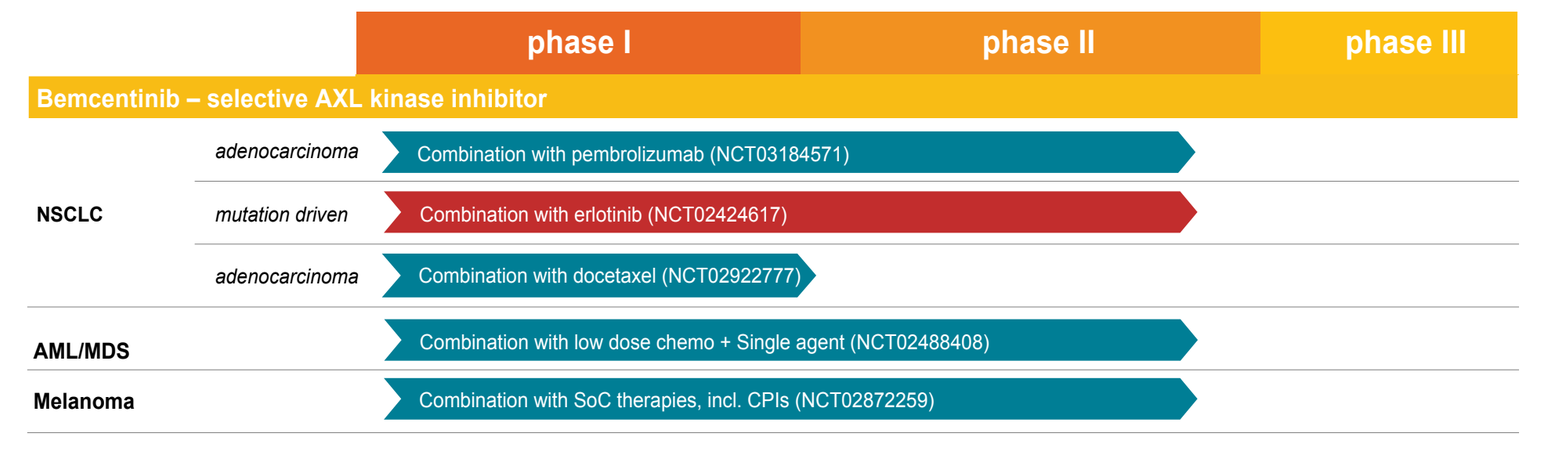

Selectivity Profile

Kinase	Kinome Scan (Kd) nM	Kinome Scan (Kd) Fold
Axl	0.4	1
Mer	100	250
Tyro	>1000	>1000

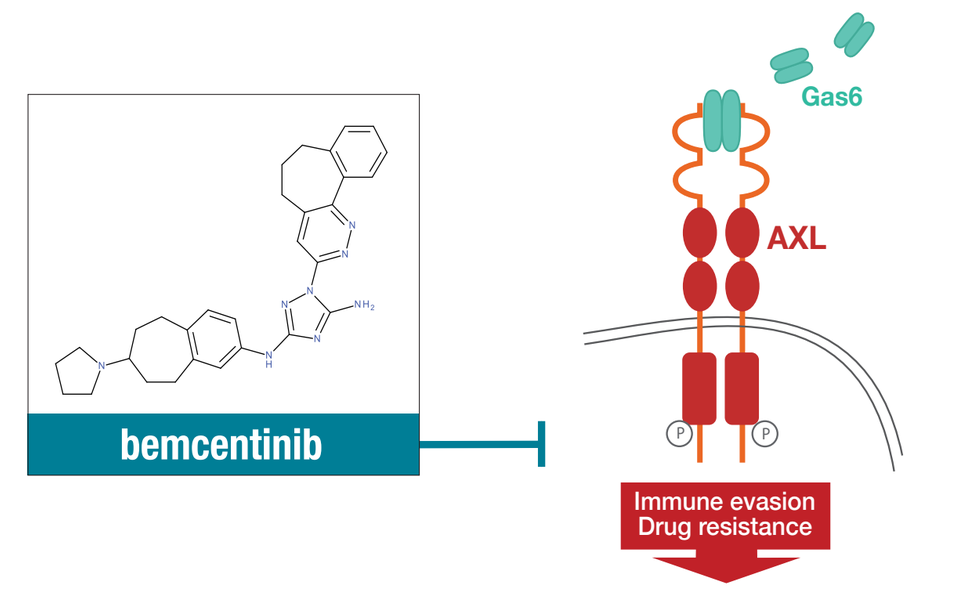

Bemcentinib is a first-in-class, oral, selective AXL TKI which is being evaluated as a combination therapy across several phase II clinical trials.

Increased AXL expression is associated with innate immune suppression and the appearance of resistance to targeted therapies in models of NSCLC and patient samples.

AXL inhibition via bemcentinib prevents the appearance of such resistance in vivo and has shown immunomodulatory effect in AML patients

Study rationale

Bemcentinib prevents therapy resistance in vivo

In vivo, erlotinib treatment induces AXL expression and activation, and resistance to erlotinib treatment emerges over time. Co-administration of the selective AXL inhibitor bemcentinib prevents resistance to erlotinib.

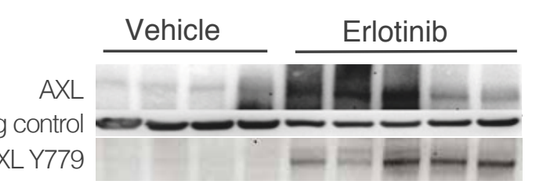

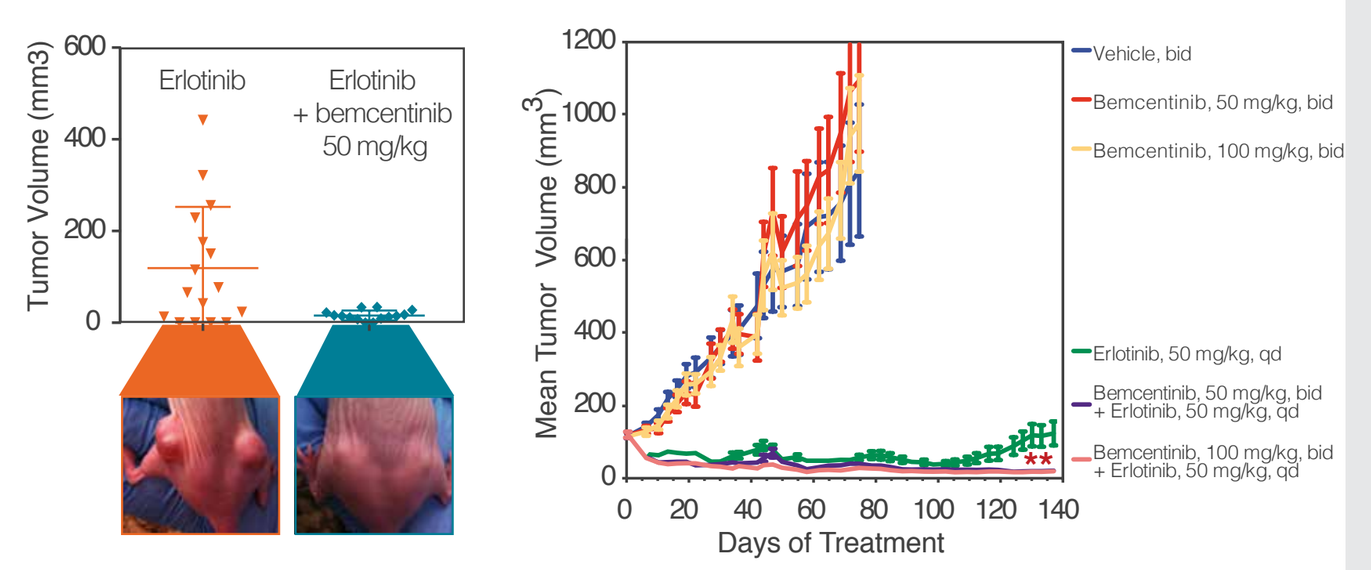

Bemcentinib induces an immunogenic cell death in erlotinib-resistant NSCLC cells

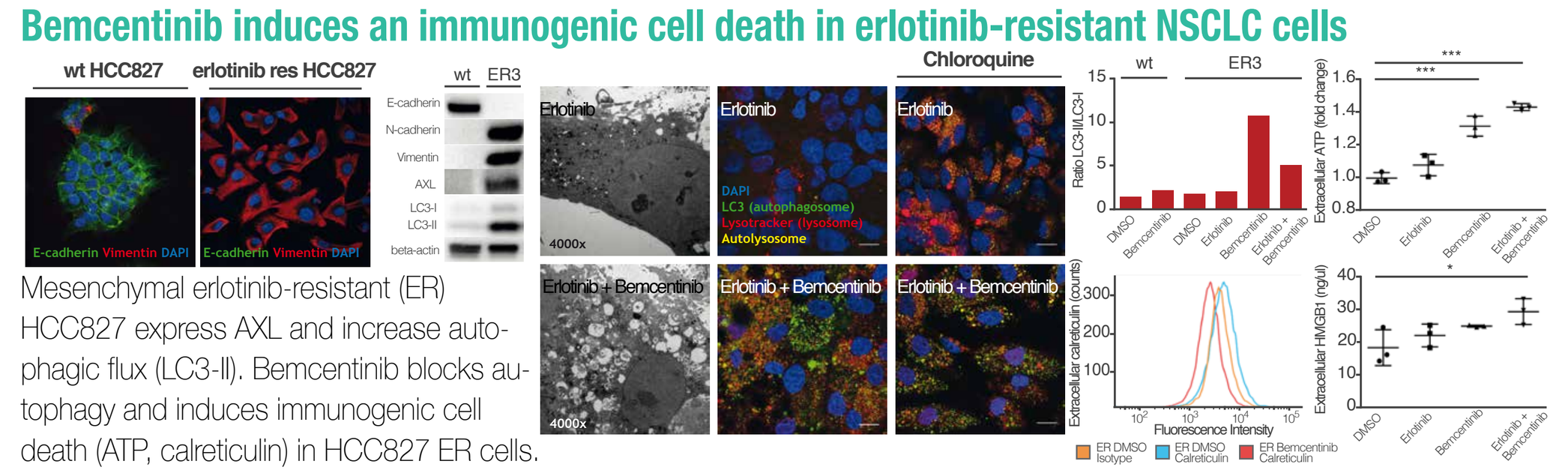

Mesenchymal erlotinib-resistant (ER) HCC827 express AXL and increase autophagic flux (LC3-II). Bemcentinib blocks autophagy and induces immunogenic cell death (ATP, calreticulin) in HCC827 ER cells.

Ph I/II study of bemcentinib in combination with erlotinib in pts with EGFRm NSCLC

This study was designed to confirm the safety and tolerability of bemcentinib as a monotherapy and when administered in combination with erlotinib (arm A).

Patients with activating EGFR mutation driven NSCLC who had progressed on an approved EGFR inhibitor (arm B) were treated with bemcentinib at RP2D in combination with full dose erlotinib to test the hypothesis whether the addition of bemcentinib may **reverse acquired resistance to erlotinib**. Both patients with and without the acquired resistance mutation T790M were enrolled.

Patients with activating EGFR mutation driven NSCLC who had received erlotinib monotherapy in first line for at least 12 weeks and who had not progressed (i.e. were in response or had stable disease, arm C) were treated with bemcentinib at RP2D in combination with full dose erlotinib to evaluate the potential of bemcentinib to **prevent acquired resistance** to EGFR targeted therapy.

Contact & acknowledgements

BerGenBio ASA
Jonas Lies vei 91
5009 Bergen
NORWAY

www.bergenbio.com
@BGenBio

Lauren Byers
MDACC Houston, TX

post@bergenbio.com
+47 559 61 159

The authors are deeply grateful to patients and their caretakers for participation in this study.

NCT02424617 (BGBC004): Phase I/II trial of bemcentinib in combination with erlotinib in patients progressing (2L resistance reversal) or patients stable (1L resistance prevention) on erlotinib

Overall Study schema

Three arm study to establish safety of the combination and test whether bemcentinib may reverse or prevent acquired resistance to erlotinib

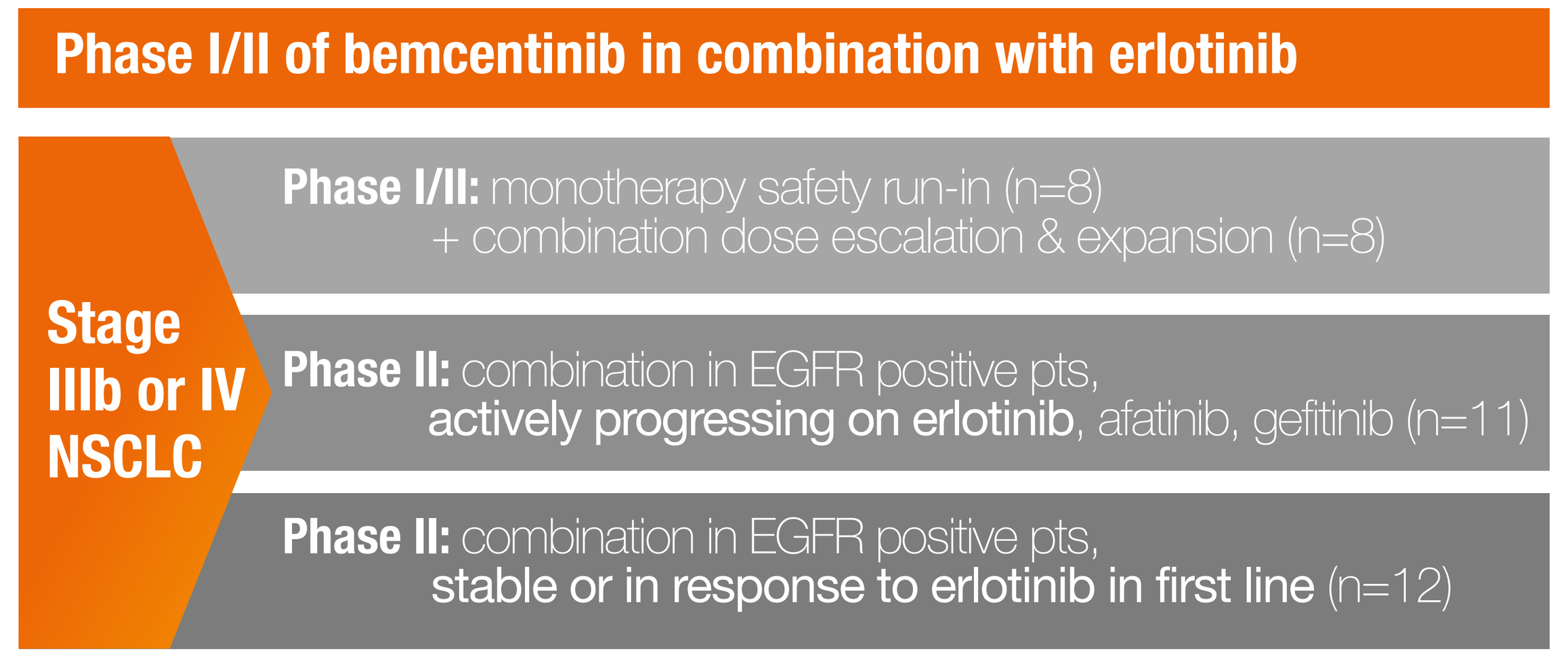

Pharmacodynamics & predictive biomarkers

Soluble AXL increases following bemcentinib treatment, indicating on-target activity

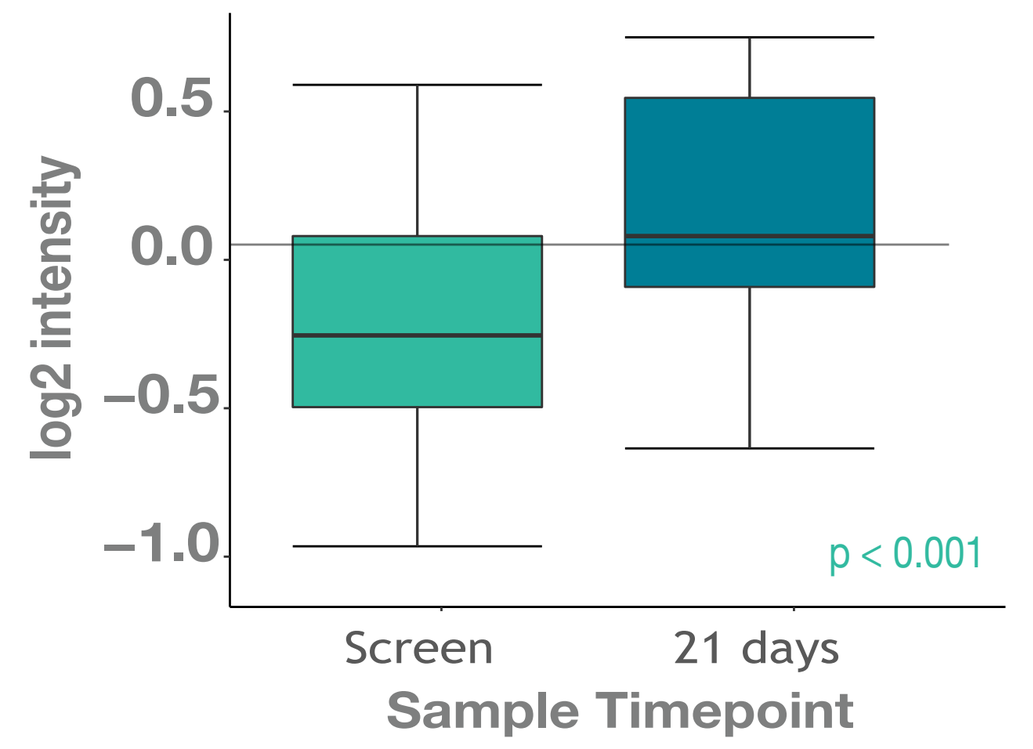

Screen levels of BGBM14* correlate with patient benefit

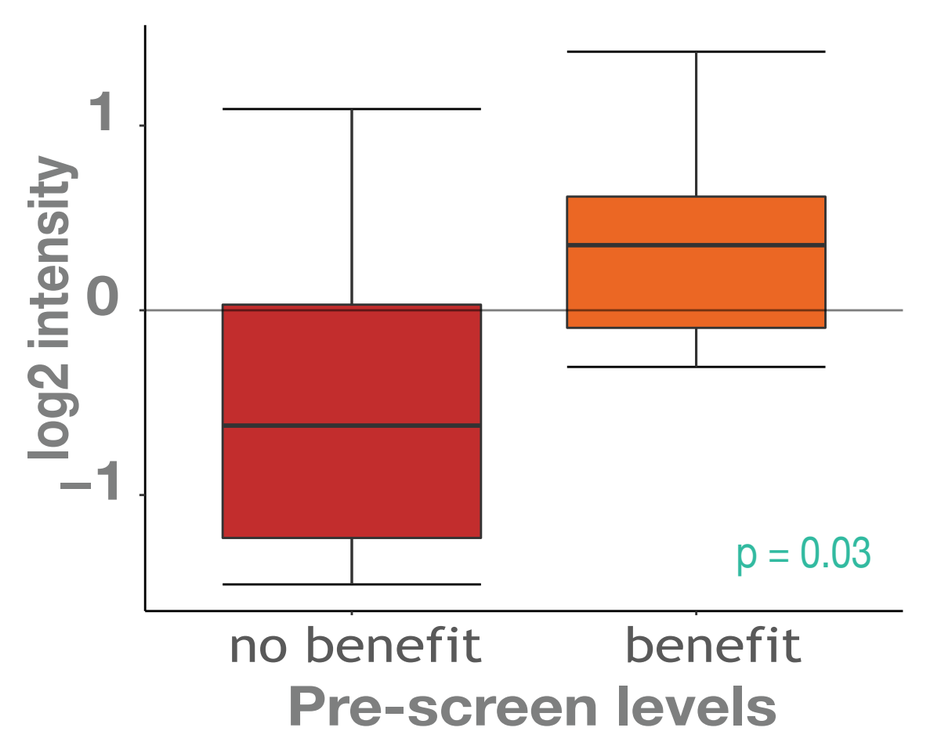

Methods: Plasma protein biomarker levels were measured using the DiscoveryMap v3.3 panel (Myriad RBM) at pre-dose and at C2D1. Bioinformatics analysis was carried out by Fios Genomics. Comparisons were performed on the QC-passed and normalised Myriad datasets comparing pre-dose and C2D1 (all patients, sAXL) or at pre-dose in patients from all three arms pooled according to evidence of tumour shrinkage (benefit) or absence of shrinkage (no benefit) (BGBM14). * Proprietary predictive biomarker candidate, patent pending

Conclusions

- 200mg daily bemcentinib + full dose erlotinib (RP2D) was well tolerated over extended periods of time.
- The erlotinib + bemcentinib combination led to disease stabilisation and tumour responses in a fraction of patients who had previously progressed on EGFR targeted therapy and were negative for the T790M resistance mutation.
- In patients who were stable or in response to 1L erlotinib, addition of bemcentinib led to further deepening of responses. The combined PFS was not mature at time of analysis but exceeded that reported for erlotinib monotherapy.
- Patient benefit could be predicted by screening levels of BGBM14 (a proprietary predictive biomarker) and exposure to bemcentinib correlated with increased levels of soluble plasma AXL (sAXL) after 1 cycle indicating selective on-target activity of bemcentinib.

Phase Ib: Previously treated patients - monotherapy and combination with erlotinib

Single arm, bemcentinib monotherapy & bemcentinib + erlotinib

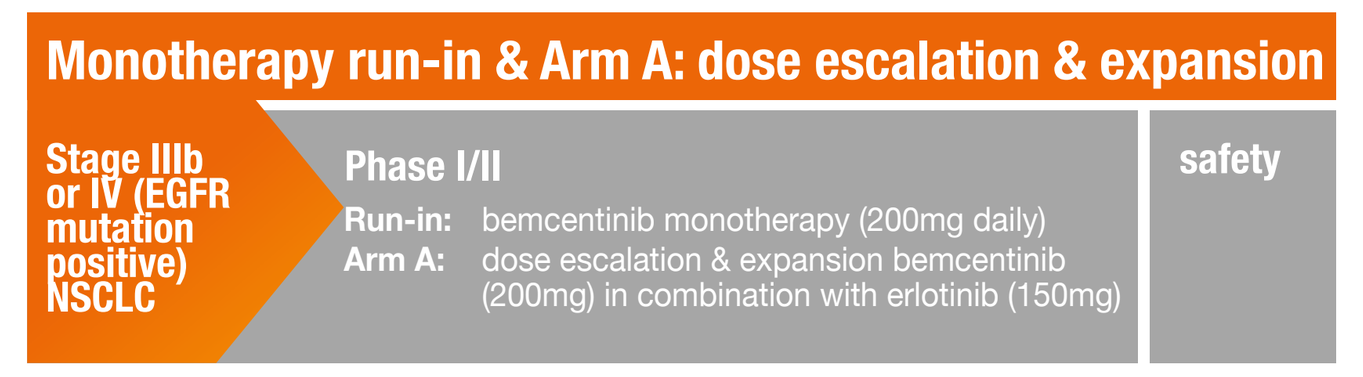

Patient characteristics

	Monotherapy (run-in) n = 8	Arm A (combination) n =8
Median age (range)	64 (58 - 77)	59 (38 - 68)
Median scrn ECOG (range)	1 (0-1)	1 (0-1)
Female (%)	5 (63%)	5 (63%)
Ethnicity		
Asian (%)	1 (13)	3 (38)
Caucasion (%)	5 (63)	5 (63)
Type of EGFR mutation		
Exon 21 insertion (%)		4 (50)
Exon 19 deletion (%)		4 (50)
Best response to previous erlotinib		
PR (%)		1 (13)
SD (%)		5 (63)
PD (%)		2 (25)

Adverse Events

Treatment related AEs (TRAEs, Grade ≥3) Preferred Term (n (%) E) Arm A	n = 8
Dermatitis acneiform	1 (13) 1
Diarrhoea	3 (38) 4
Monotherapy (run-in)	**n = 8**
No TRAEs grade 3 or higher reported	

Best % change sum target lesions

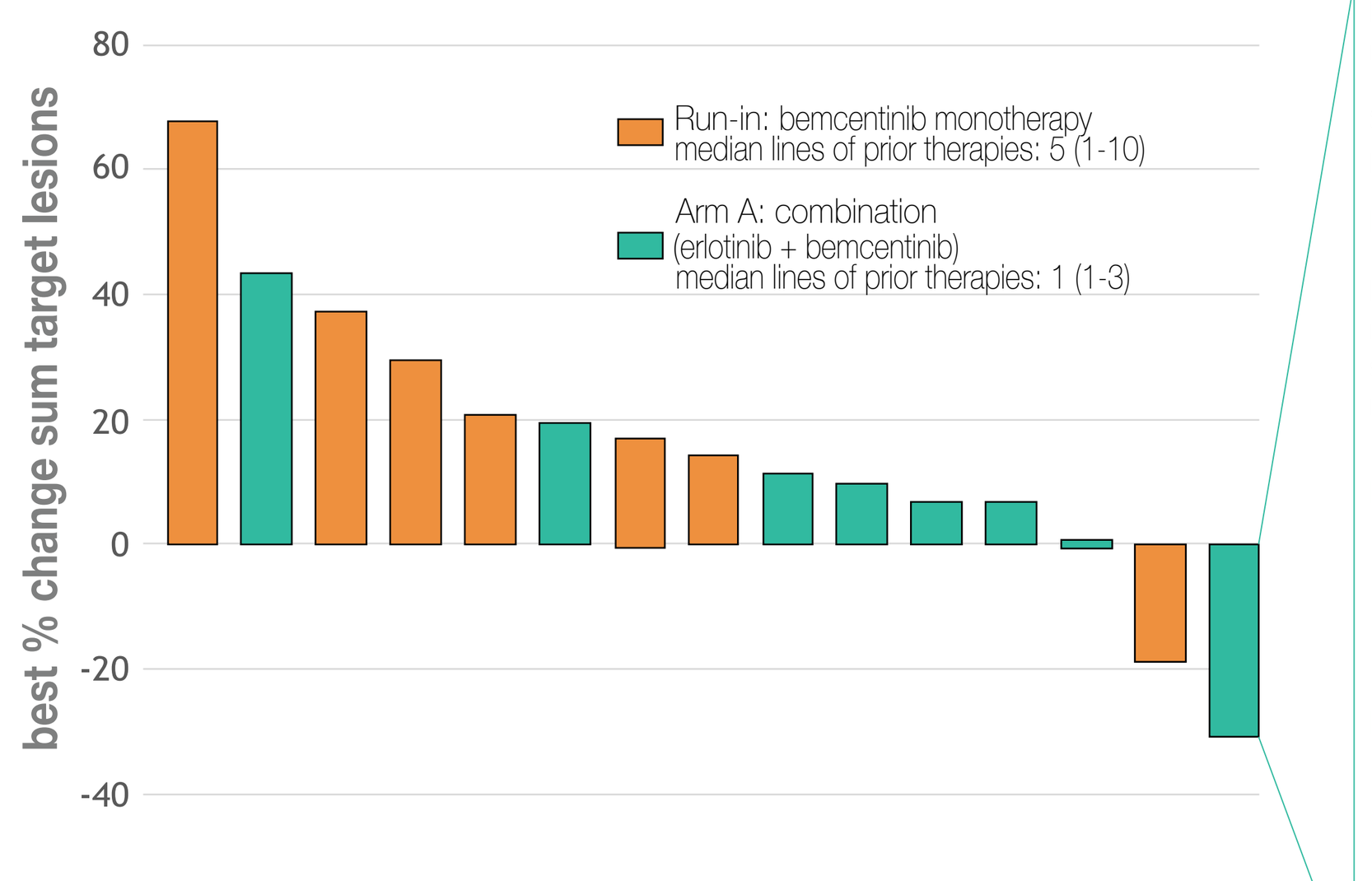

Patient 311210

Patient is a 68-year-old white female, diagnosed with stage IV adenocarcinoma of the lung. Metastases outside of the lung found in bone.

She has been on two treatment regimens, one being erlotinib, prior to participation in this trial.

Best response on trial: SD (23+ months)

Patient had confirmed stable disease for **710 days (23.7 months)**. She remains on trial deriving clinical benefit. As of Sept 5 2018, her total exposure to bemcentinib in combination with erlotinib has been **930 days (30.5 months).**

Mutation status

- EGFR status: positive
- Specific mutation: exon 21 insertion
- Mutation details: exon 21 L858R substitution mutation
- T790M mutation status: unknown

Previous cancer treatment regimens

- Regimen 1: Dacomitinib (09/02/2015-18/10/2015) **Best response: PR**
- Regimen 2: Other: Erlotinib (26/10/2015-14/02/2016) **Best response: SD**

Change in sum target lesion over time, by patient (%)

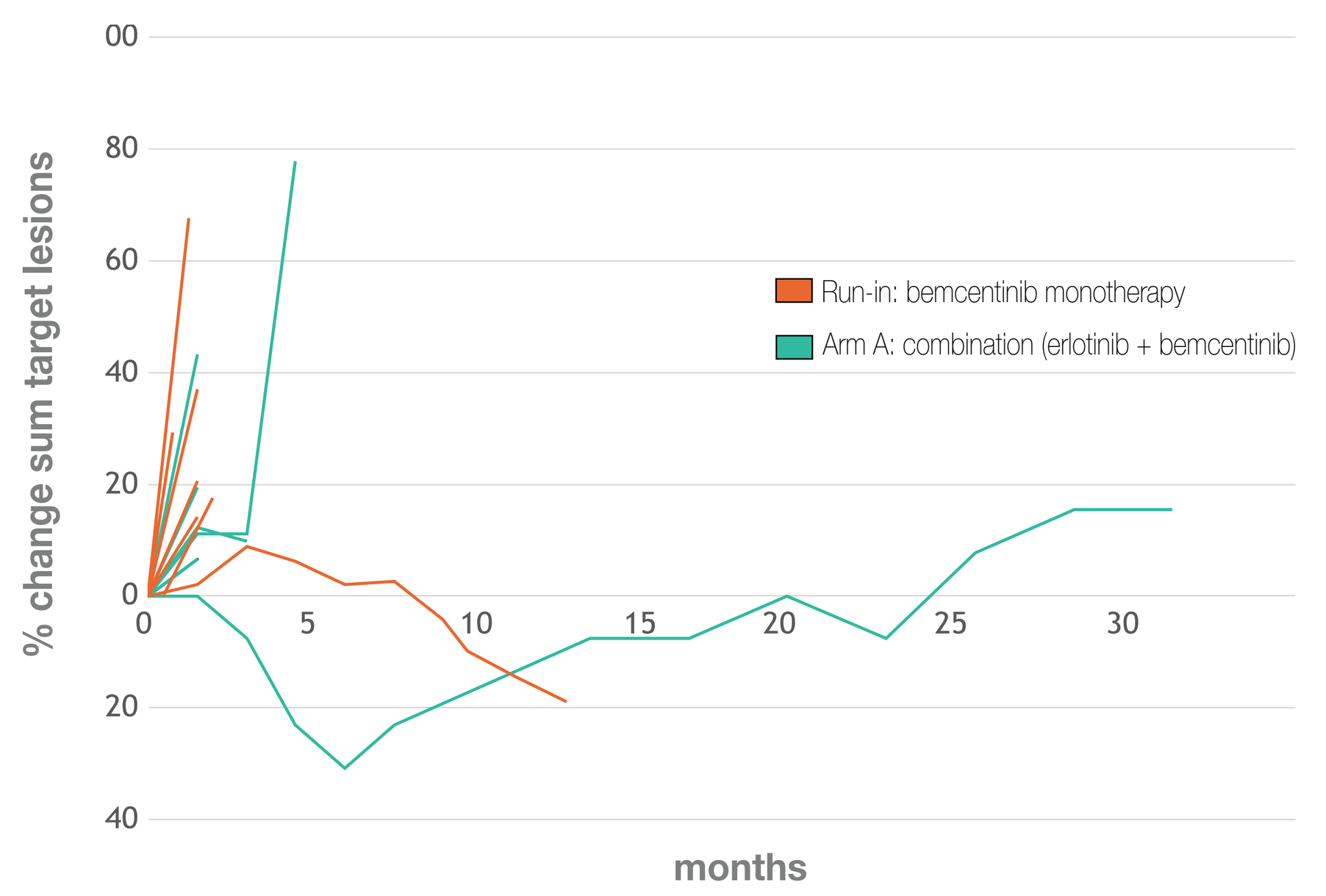

Progression Free Survival

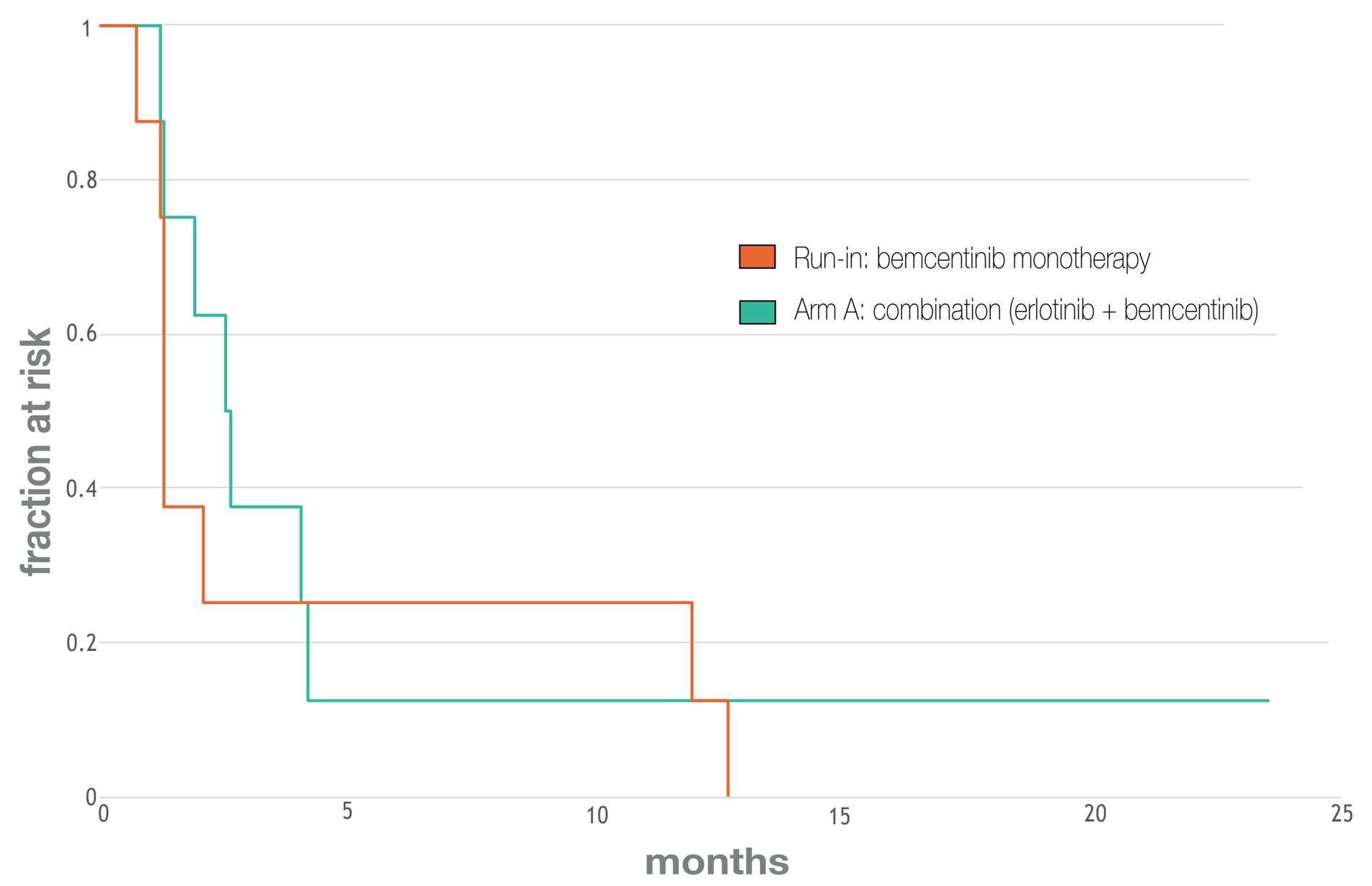

Phase II: 2L patients with activating EGFR mutation driven NSCLC actively progressing on an approved EGFR inhibitor

Single arm, bemcentinib + erlotinib

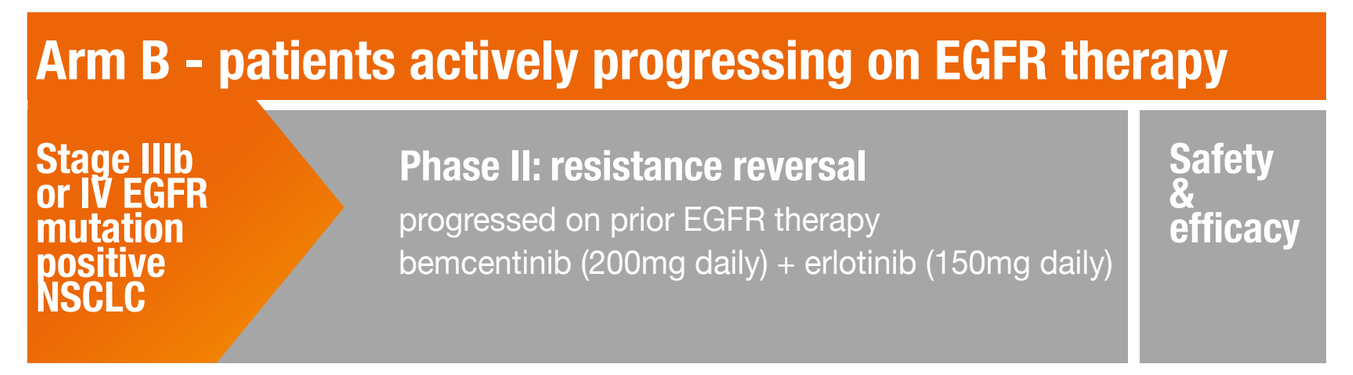

Patient characteristics

	T790M positive n = 6	T790M negative n = 5
Median age (range)	70 (49-78)	63 (52-69)
Median scrn ECOG (range)	1 (1)	1 (0-1)
Female (%)	4 (67)	3 (60)
Ethnicity		
Hispanic or latino (%)	0 (0)	0 (0)
Not hispanic or latino (%)	6 (100)	5 (100)
Type of EGFR mutation		
Exon 21 insertion (%)	3 (50)	1 (20)
Exon 19 deletion (%)	3 (50)	3 (60)
Unknown	0 (0)	1 (20)
Median prior lines (range)	5 (2-7)	3 (1-12)
Best response to previous erlotinib*		
PR (%)	5 (83)	1 (13)
SD (%)	0 (0)	5 (63)
PD (%)	1 (17)	2 (25)
Other	0 (0)	1 (20)

Adverse Events

Treatment related AEs (TRAEs, Grade ≥3) Preferred term, n (%) E	n = 11
Diarrhoea	2 (18) 3
Rash	1 (9) 1

*best response to erlotinib monotherapy, before entering the trial

Best % change sum target lesions

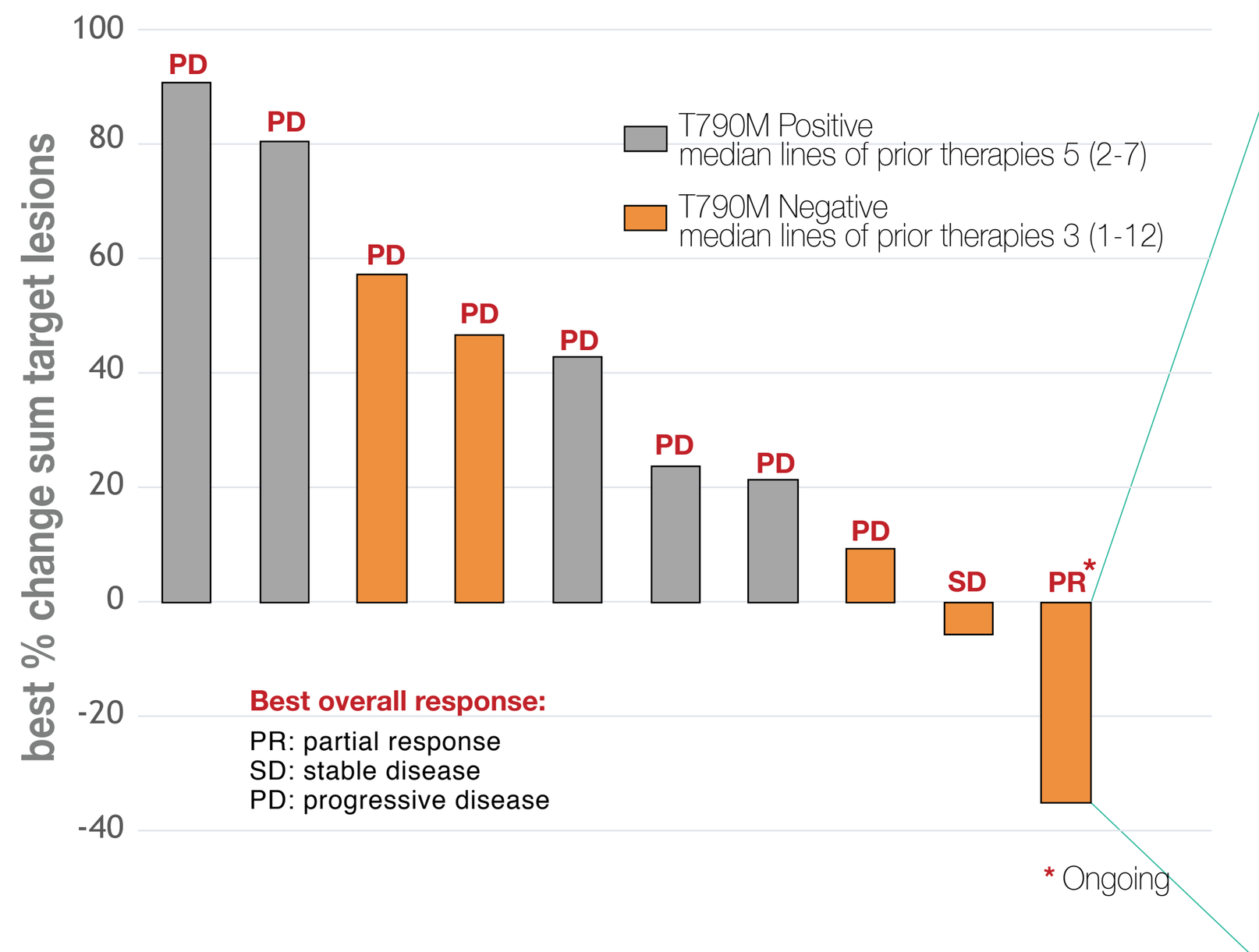

Patient 320334

Patient is a 52-year-old white male, diagnosed with stage IV adenocarcinoma of the lung. Metastases outside the lung found in liver, pleura and lymph nodes.

He has been on three cancer treatment regimens prior to participation.

Best response on trial: PR (7+ months)

As of Sept. 5, 2018 he has been on treatment with bemcentinib + erlotinib for **344 days (11.3 months)** without signs of progression.

Mutation status

- EGFR status: positive
- Specific mutation: exon 21 insertion
- Mutation details: EGFR point mutation, Leu861GLN on exon 21
- T790M mutation status: **negative**

Previous cancer treatment regimens

- Regimen 1: Pemetrexed/Carboplatin + erlotinib **Best response: PR**
- Regimen 2: Nivolumab **Best response: PD**
- Regimen 3: Docetaxel **Best response: PD**

Change in sum target lesion over time, by patient (%)

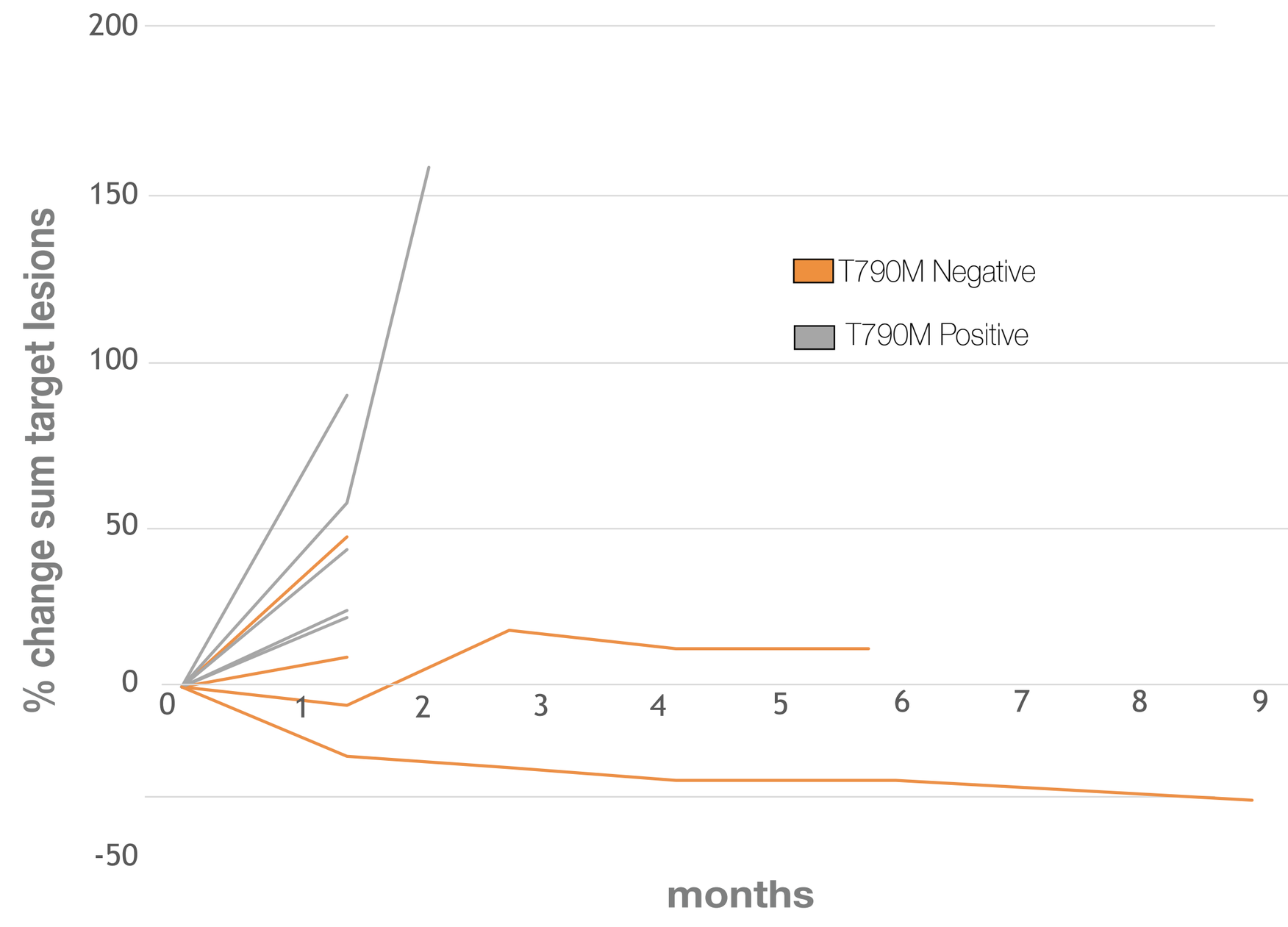

Progression Free Survival

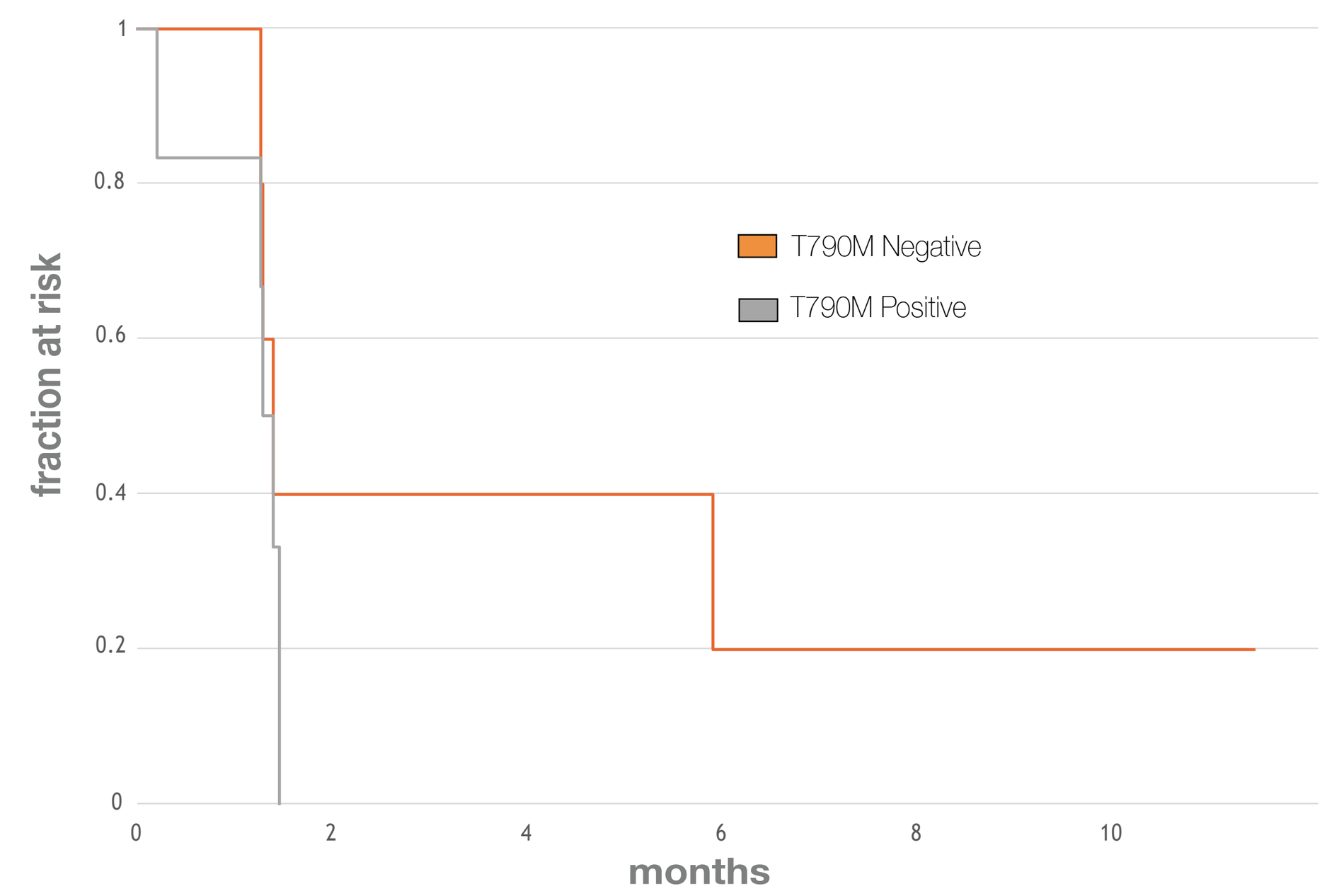

Phase II: 1L patients with activating EGFR mutation driven NSCLC stable or in response on erlotinib

Single arm, bemcentinib + erlotinib

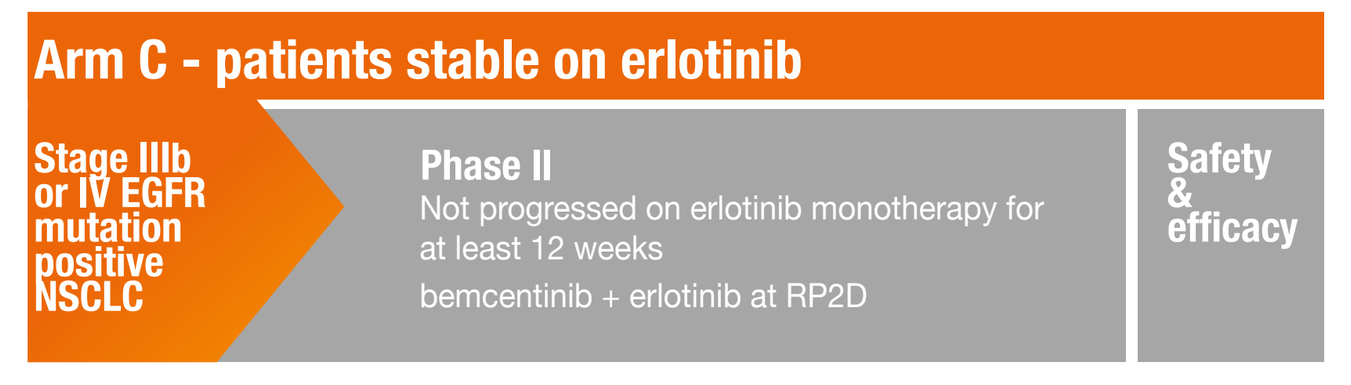

Patient characteristics

	n = 12
Median age (range)	68 (32-80)
Median screen ECOG (range)	1 (0-1)
Female (%)	9 (75)
Ethnicity	
Hispanic or latino (%)	1 (8)
Not hispanic or latino (%)	11 (92)
Type of EGFR mutation	
Exon 21 insertion (%)	4 (33)
Exon 19 deletion (%)	8 (67)
Best response to erlotinib monotherapy*	
PR (%)	4 (33)
SD (%)	5 (42)
Unknown (%)	3 (25)

Adverse Events

Treatment related AEs (TRAEs, Grade ≥3) Preferred term, n (%) E	n = 12
Aspartate aminotransf. inc.	1 (8) 1

*best response to erlotinib monotherapy, before entering the trial

Best % change sum target lesions

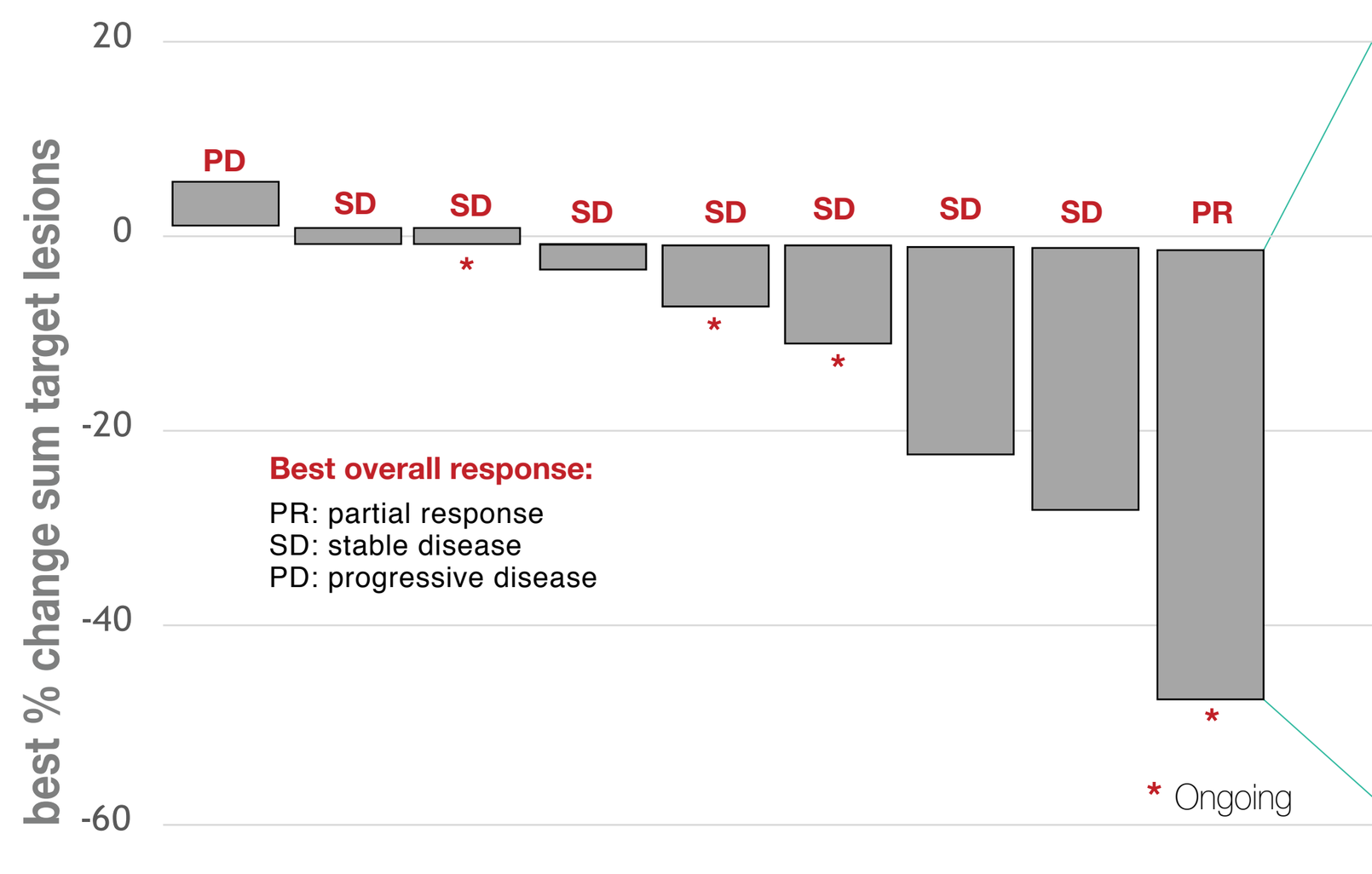

*** Patients who have not undergone 1 full cycle and first tumour assessment after screening were not included

Patient 316428

Patient is a 58-year old male of mixed race, diagnosed with stage IV adenocarcinoma of the lung. Metastases outside the lung found in the pleura.

When entering the trial, he had been receiving 1L erlotinib for 96 days.

Best response on trial: PR (6.5+ months)

Patient had been on treatment with bemcentinib for **249 days (345 days, including erlotinib monotherapy period pre-trial = 11.3 months in total)** before progressing. Patient continues on treatment as clinical benefit is still being seen.

Mutation status

- EGFR status: positive
- Specific mutation: exon 19 deletion
- Mutation details: EGFR point mutation, L747_A750delinsP
- T790M mutation status: unknown / NA

Change in sum target lesion over time, by patient (%)

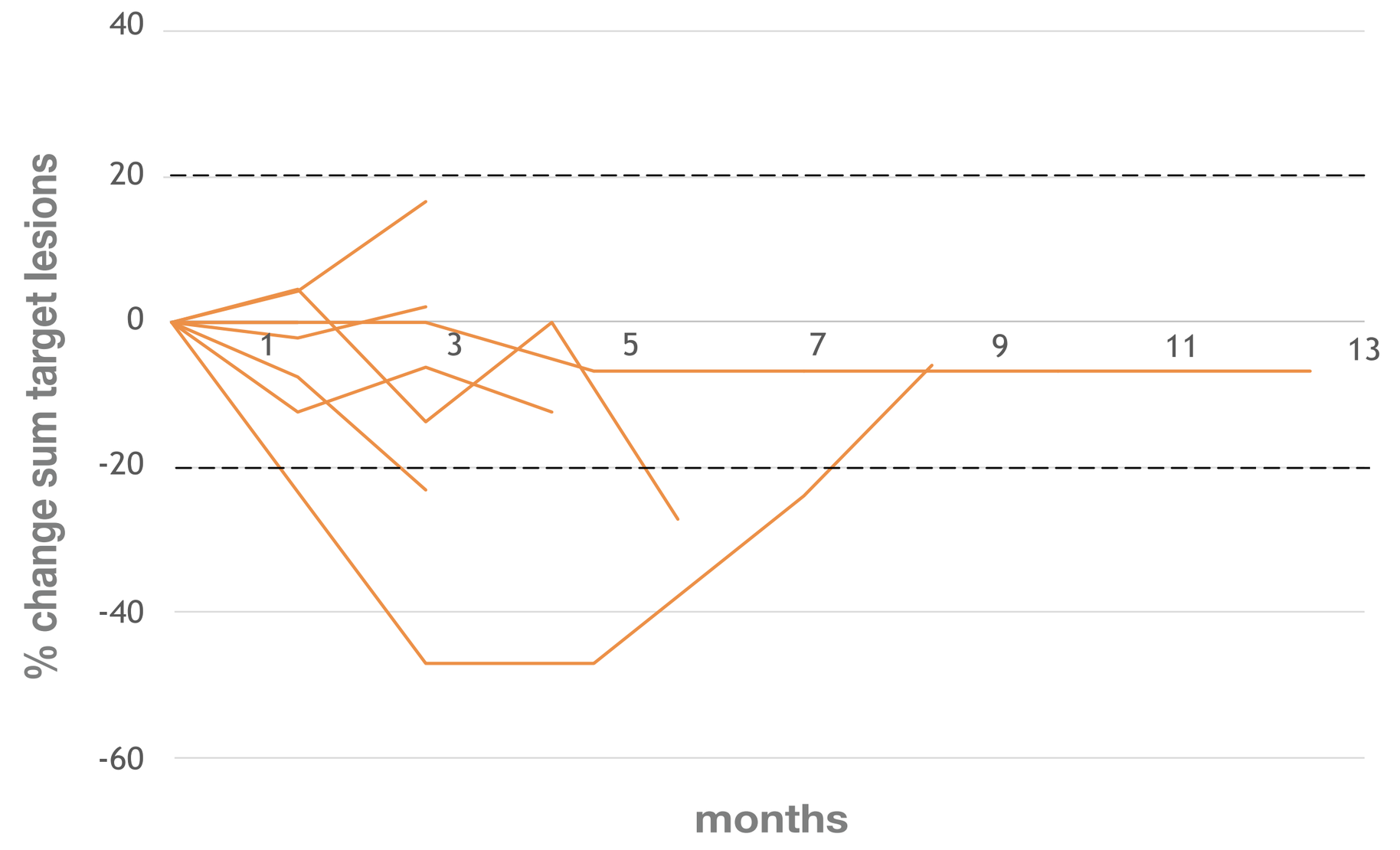

Progression Free Survival (combined*)

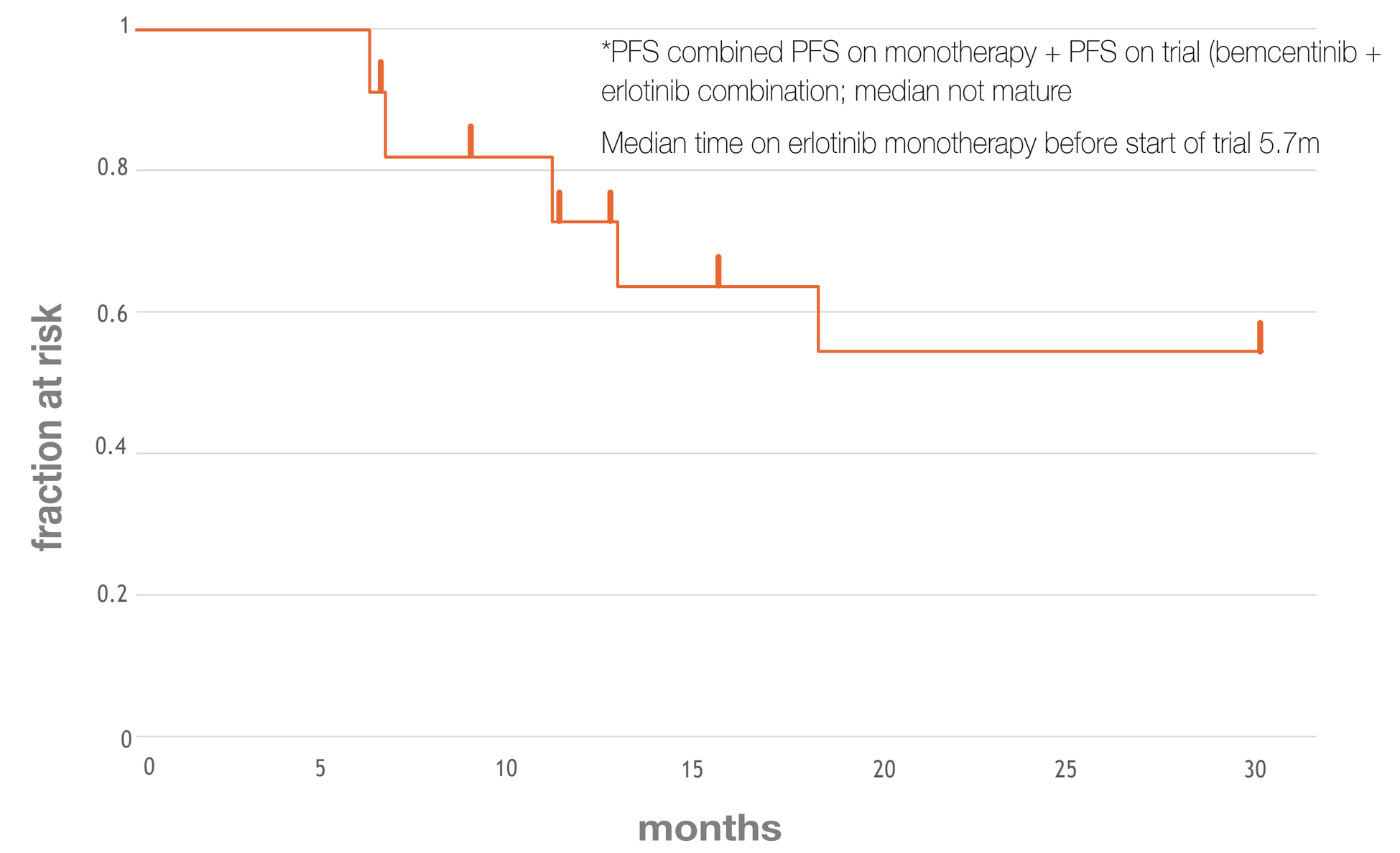

This presentation is the intellectual property of the presenter. Contact them at post@bergenbio.com for permission to reprint and/or distribute.

This poster was presented at the 19th World Conference on Lung Cancer, Toronto, Canada (Sep 23 - 26, 2018)